

## Bones that cats gnawed upon: a case study in bone modification

N. C. Moran and T. P. O'Connor, *Department of Archaeological Sciences, University of Bradford, Bradford BD7 1DP, U.K.*

### Summary

The role of cats in producing gnawing damage to mammal bones in human occupation debris is briefly discussed. The results obtained by allowing a domestic cat to chew discarded sheep bones *ad lib* are presented, and it is concluded that cats produce a characteristic pattern of damage which may be distinguishable from that produced by dogs.

### Introduction

It has long been recognised that scavenging carnivores and omnivores are an important factor in the taphonomy of archaeological and palaeontological bone assemblages. The recognition of surface damage caused by scavengers has been of particular importance in the examination of Pleistocene assemblages, when hominids may have been among the scavengers (Shipman 1981). In more recent archaeological assemblages, the emphasis has been more on recognising the pattern of bone destruction, and thus removal from the archaeological record, which may result from such scavenging, and observations have been made on the destructive effects of bone chewing by, *inter alia*, foxes (Stallibrass 1984), dogs (Stallibrass 1990, Payne and Munson 1985), pigs (Greenfield 1988) and humans (Jones 1986). The result of most of this work has been to increase awareness of the potential attrition of deposited assemblages before burial, and to indicate the form of the surface damage which may be taken as characteristic of the gnawing and chewing of bones by different species.

In all of this work, the domestic cat has not figured large, even though cats have a long history of mutualistic co-existence with people, and observations of modern cats would suggest that they are just as liable to scavenge discarded refuse as are dogs or pigs. There may be a contemporary social factor at work in this exclusion, namely the Western premise that one feeds bones to dogs, but not to cats. In order to investigate the possibility that cats will produce a characteristic pattern of surface damage, a long-term feeding experiment was devised. The experiment was

undertaken by TO'C; the bones were examined and the results collated by NCM.

### Materials and methods

Limited empirical observation suggested that it would be a mistake to start by feeding too many different types of bone to too many cats, as the results would be complex to collate and to standardise for any one variable. Accordingly, it was decided to limit the experiment to two types of bone, with a standard treatment prior to feeding them to one cat. Pragmatism dictated that the bones should be readily available as domestic refuse, so sheep scapulae and humeri were chosen. These were available at roughly fortnightly intervals as debris from a roasted shoulder of lamb, thereby standardising the treatment undergone by the bones (around 90 minutes at 200°C in a closed container; the presence or absence of rosemary or garlic was not thought to be significant!). The rather long interval between each feeding ensured that neither the cat nor the experimenter became bored with the procedure. The same cat, an elderly neutered male, co-operated enthusiastically throughout the period of feeding experiments.

Following cooking of the shoulder of lamb, and removal of most of the meat, the bones were allowed to cool, and were then offered to the cat. The cat was always given the bones in the same place, an area of grass close to 'home' and known not to be frequented by other cats or dogs. The cat was left to do whatever it wished with the bones, with no interference and minimal direct observation. Interest in the bones generally waned after an hour or so, but the bones were left in the same place for up to 24 hours to ensure that any

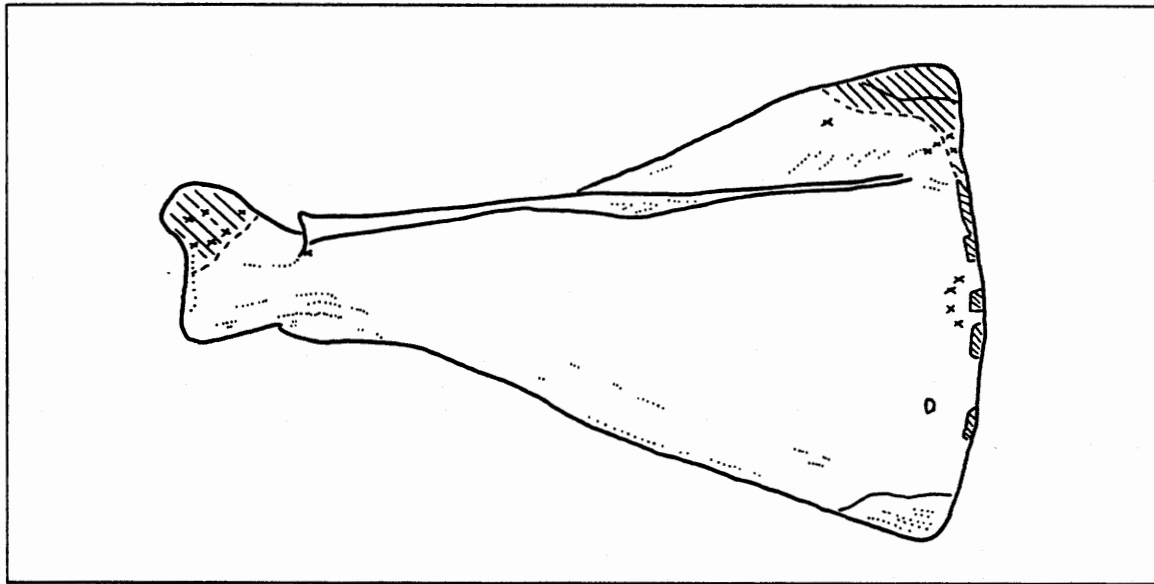


Figure 12. Diagram to show the principal areas of surface damage on the scapula. The experiment included both left and right specimens: where necessary, the records of individual bones have been laterally inverted to produce this summary. Hatching shows areas of general surface damage and destruction: discrete isolated 'punctures' are marked by a cross.

scavenging activity had ceased. The bones were then removed to a protected corner of the garden between a fence and a densely prickly shrub, where sub-aerial weathering could occur for several weeks without further disturbance by mammalian scavengers. The purpose of this weathering was to ensure the decay of any remaining soft tissue and fat. Finally the bones were collected and cleaning was completed by a period of simmering in water, followed by drying in a ventilated cabinet.

By mid-1991, sufficient specimens had accumulated to justify some collation of results. The increasing age of the cat also made it advisable to terminate the experiment.

## Results

Thirteen sheep scapulae and thirteen sheep humeri were examined macroscopically for surface damage which might have resulted from chewing or gnawing. At least some damage was found on nearly all of the specimens examined. In a small proportion, this took the form of the destruction of particular areas of bone, usually the edges or protruberances. More commonly, an area of grooves and pits would be apparent, evidence

of repeated biting on some parts of the bone. Away from these concentrated areas of damage, isolated pits and 'punctures' in the bone were noted.

Each specimen was recorded by noting the location of areas of damage and isolated punctures on a *pro forma* which provided outline diagrams of different aspects of the bones. The individual records were then merged by tracing all the observations onto one diagram of each of the elements. These concatenated diagrams are presented as Figs. 12 and 13.

On the humerus, gnawing activity concentrated on the epiphyses. This was presumably because the epiphyses have a large quantity of attached soft tissue and are composed of relatively soft bone. However, this pattern of damage may also reflect the cat's habit of placing a paw on the diaphysis to keep the bone still during gnawing. At the proximal end, the tubercles showed the most frequent damage, with many small areas of destruction. The proximal articular surface also commonly bore patches of grooves and punctures. On the distal epiphysis, the pattern of damage was generally similar, with tooth marks distributed across the epiphysis.

Damage on the scapulae was concentrated along the suprascapular margin, particularly at the superior angles, and around the coracoid. Surprisingly little damage was noted along the scapular spine.

Examples of typical tooth marks and damage are shown in Figs. 14-17. Tooth marks typically show clearly defined margins, and are narrow in proportion to their depth. Paired punctures, such as those seen on the suprascapular margin in Fig. 16 are frequent, and may reflect the distinctive form of the feline lower first molar.

## Discussion

It is clear that a cat, even when not driven by the extremes of hunger, can inflict appreciable surface damage to the bones of a medium-sized ungulate. Considerable destruction of bone is unlikely, and the damage typically takes the form of more or less dispersed tooth marks. In this respect, the damage differs from that produced by canids, which seem more inclined to 'mumble' bones, producing heavily gnawed areas on which individual tooth marks merge into a mass of shallow pits and grooves. The more dispersed and clearly

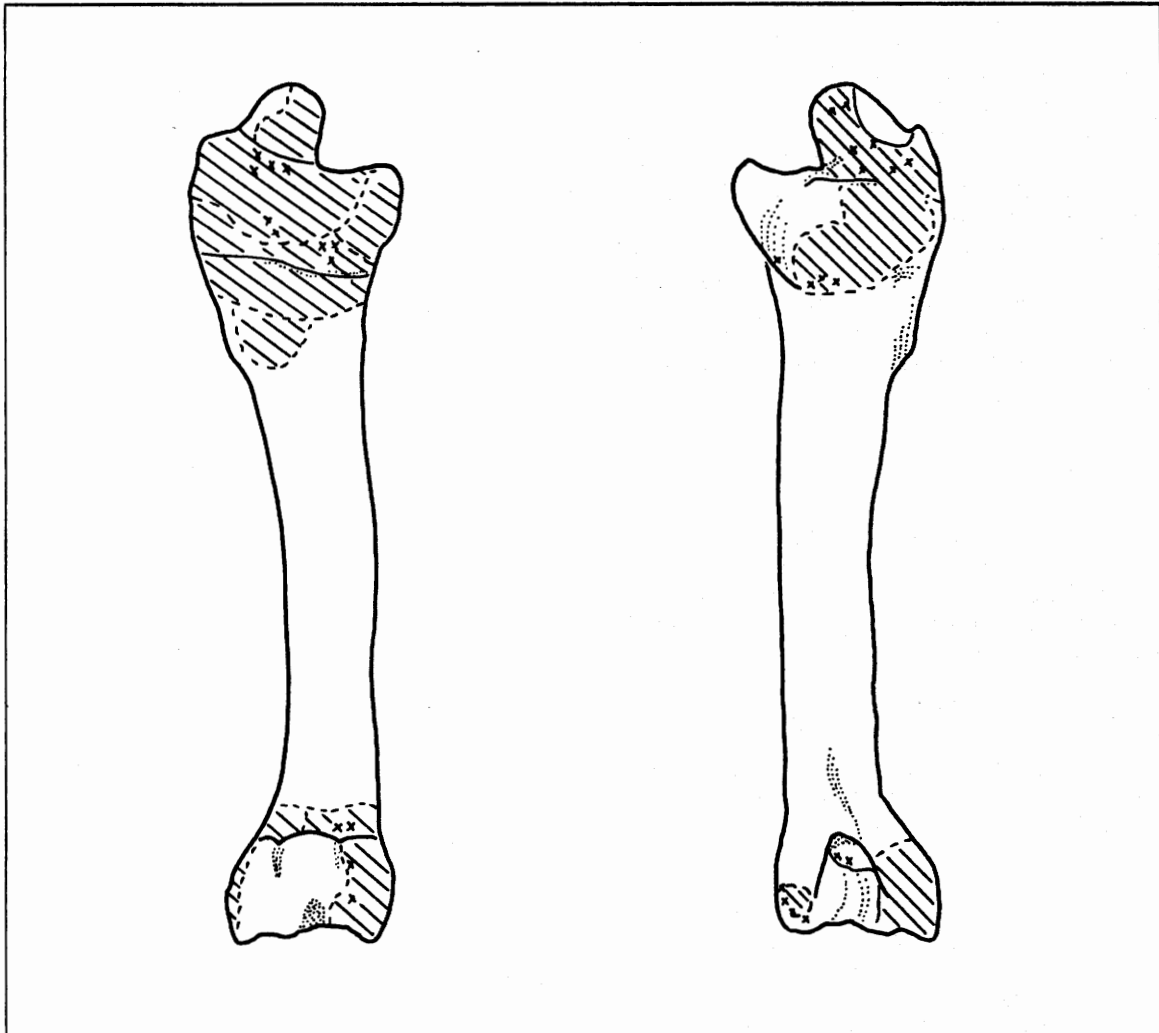


Figure 13. Diagram to show the principal areas of surface damage on the humerus. The experiment included both left and right specimens: where necessary, the records of individual bones have been laterally inverted to produce this summary. Hatching shows areas of general surface damage and destruction: discrete isolated 'punctures' are marked by a cross.

defined tooth marks produced in this experiment by a cat would seem to be distinctive, as would the relatively deep and narrow profile of those tooth marks. Some of the damage caused, for example, to the suprascapular margin and the coracoid would appear to be the consequence of attempts to remove conjoining soft tissue, but some of the other tooth marks may represent 'handling' of the bones or, perhaps, a form of play.

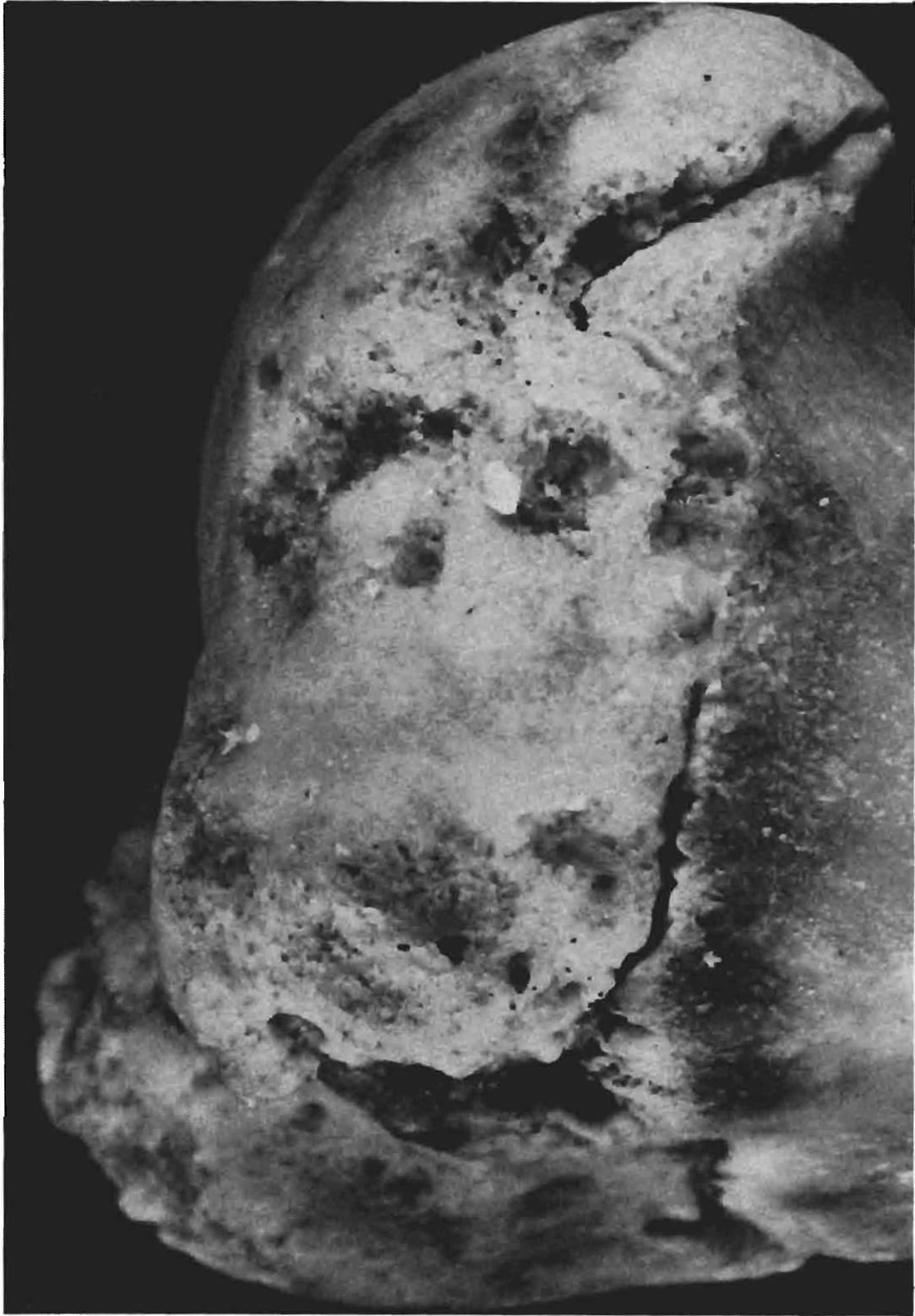Clearly, this paper presents only the results of one rather *ad hoc* experiment, and illustrates the surface modifications caused by one cat on two skeletal elements of one ungulate species. Without wishing to encourage the undue proliferation of gnawing experiments, there is evidently a need for further work to establish whether bone modification by cats is consistent enough to be reliably distinguished from that caused by dogs, and to determine whether cats can, or more importantly will, wholly destroy the bones of smaller vertebrates. Having established the criteria by which to recognise feline tooth marks, the next step will be their routine recognition on archaeological material, thereby adding a little more detail to our knowledge of assemblage formation processes on occupation sites.

## References

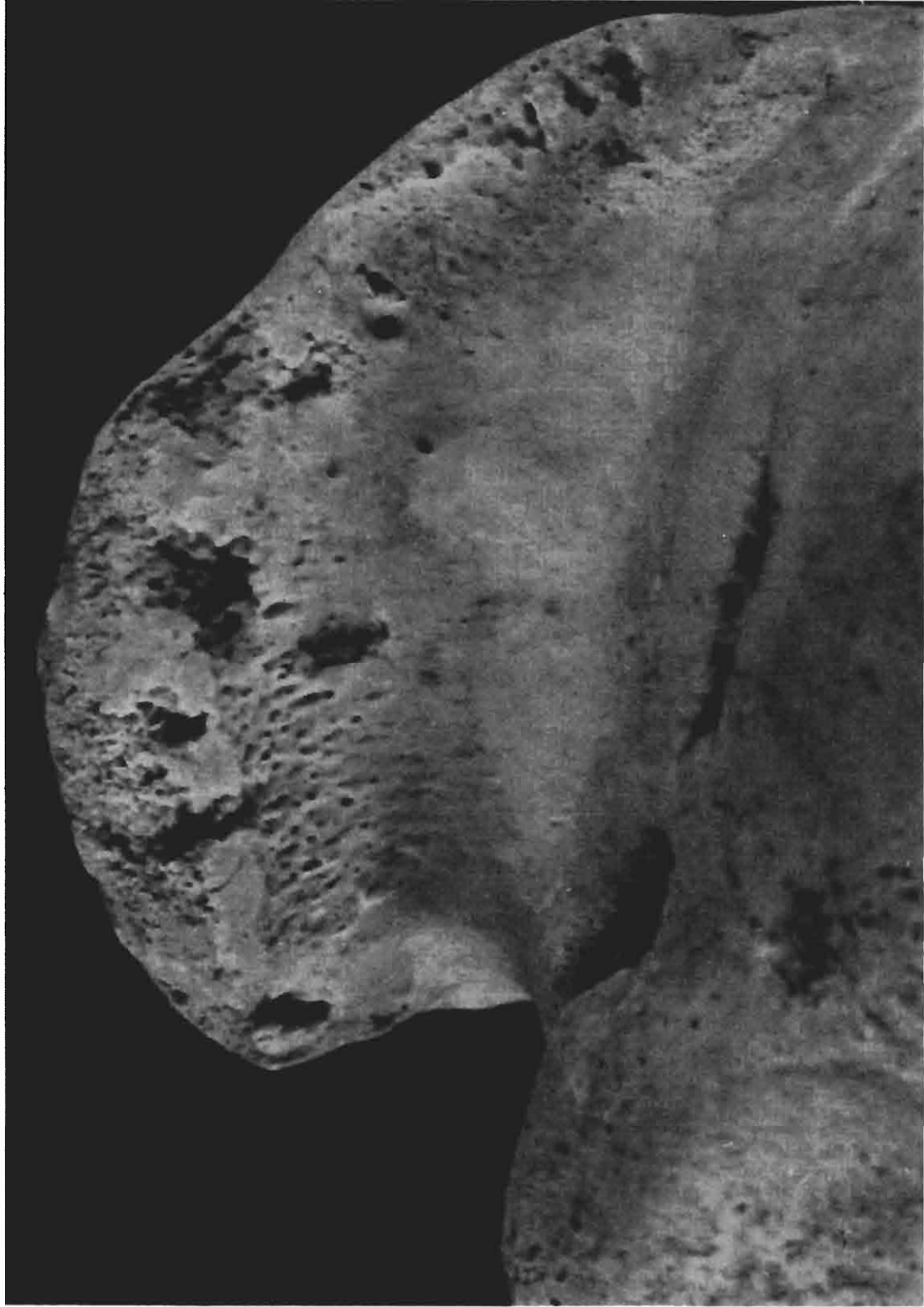- Greenfield, H. J. (1988). Bone consumption by pigs in a contemporary Serbian village: implications for the interpretation of prehistoric faunal assemblages. *Journal of Field Archaeology* 15, 473-9.
- Jones, A. K. G. (1986). 'Fish bone survival in the digestive systems of pig, dog, and man', pp.53-61 in D. Brinkhuizen and A. Clason (eds.) *Fish and Archaeology. British Archaeological Reports, International Series 294*. Oxford.
- Payne, S. and Munson, P. J. (1985). 'Ruby and how many squirrels? The destruction of bones by dogs', pp. 31-48 in N. Fieller, D. Gilbertson and N. Ralph (eds.) *Palaeobiological Investigations. Research designs, methods and data analysis. British Archaeological Reports, International Series 266*. Oxford.
- Shipman, P. (1981). *Life history of a fossil*. Harvard: University Press.
- Stallibrass, S. M. (1984). 'The distinction between the effects of small carnivores and humans on Post-Glacial faunal assemblages' pp. 259-69 in C. Grigson and J. Clutton-Brock (eds.) *Animals and Archaeology 4. Husbandry in Europe. British Archaeological Reports, International Series 226*. Oxford.
- Stallibrass, S. M. (1990). 'Canid damage to animal bones: two current lines of research', pp. 151-66 in D. E. Robinson (ed.) *Experiment and reconstruction in environmental archaeology*. Oxford: Oxbow Books.

Disk copy received: October 1991

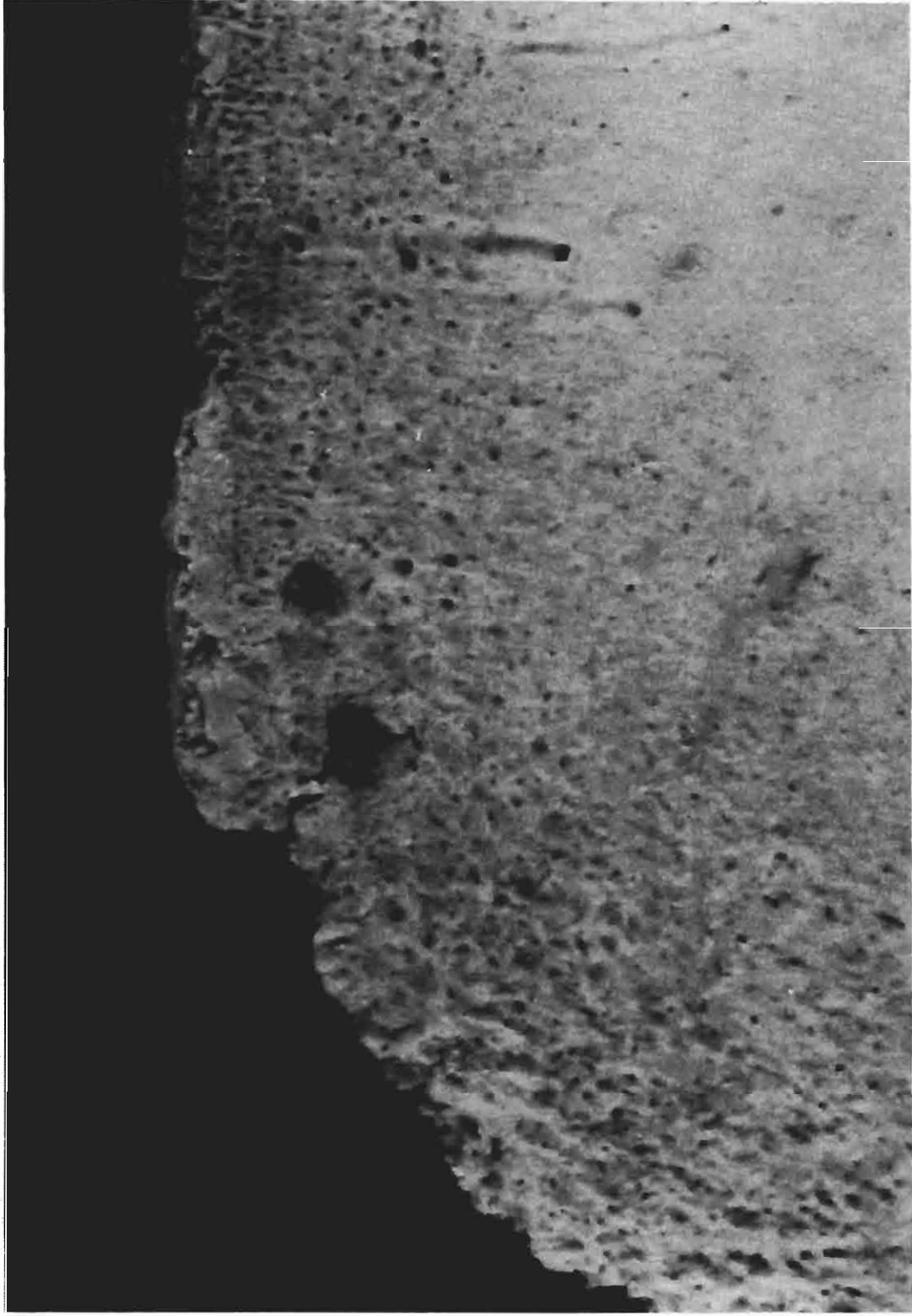
Figures 14-17 appear on pages 31-4.



*Figure 14. Humerus, proximal epiphysis, showing damage apparently caused by repeated biting on a small area.*



*Figure 15. Humerus, proximal epiphysis, showing clearly defined deep and narrow tooth marks.*



*Figure 16. Scapula, suprascapular margin, showing a paired puncture. The centres of the two holes on this specimen are 2.9mm apart.*

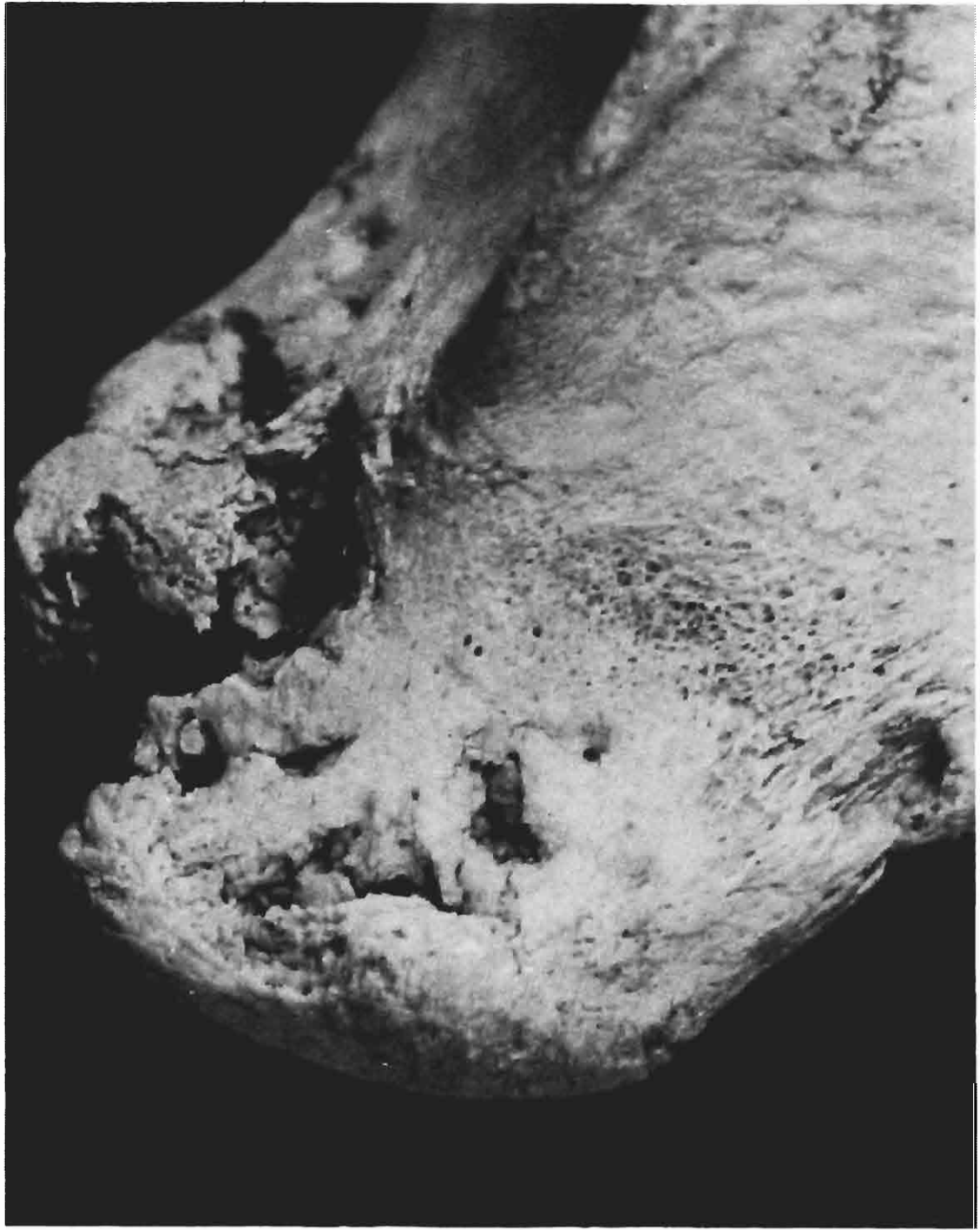

Figure 17. Scapula, coracoid process, showing appreciable destruction of bone.